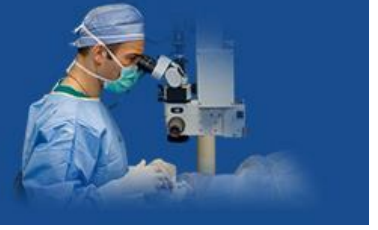

# International Journal of Medical Ophthalmology



E-ISSN: 2663-8274  
P-ISSN: 2663-8266  
[www.ophthalmoljournal.com](http://www.ophthalmoljournal.com)  
IJMO 2019; 1(2): 37-39  
Received: 21-05-2019  
Accepted: 25-06-2019

**Dr. Monika**  
Senior Resident, Regional  
Institute of Ophthalmology,  
PGIMS Rohtak, Haryana,  
India

**Dr. JP Chugh**  
Senior Professor, Regional  
Institute of Ophthalmology,  
PGIMS Rohtak, Haryana,  
India

**Dr. RS Chauhan**  
Professor, Regional Institute  
of Ophthalmology, PGIMS  
Rohtak, Haryana, India

**Dr. Ashok Rathi**  
Professor, Regional Institute  
of Ophthalmology, PGIMS  
Rohtak, Haryana, India

**Corresponding Author:**  
**Dr. Monika**  
Senior Resident, Regional  
Institute of Ophthalmology,  
PGIMS Rohtak, Haryana,  
India

## Role of intrastromal voriconazole in recalcitrant fungal keratitis

**Dr. Monika, Dr. JP Chugh, Dr. RS Chauhan and Dr. Ashok Rathi**

**DOI:** <https://doi.org/10.33545/26638266.2019.v1.i2a.19>

### Abstract

**Objectives:** To study role of intrastromal voriconazole in recalcitrant fungal Keratitis.

**Material and Methods:** 30 cases of fungal keratitis who were having >50% stromal thickness involvement and not showing good response to topical Natamycin (5%) and topical Voriconazole (1%) eye drops were included in the study. Cases with impending or frank perforation, involvement of sclera or endophthalmitis were excluded from the study. 50 microgram/0.1 ml of Voriconazole was injected with a 30G needle in midstoma, divided equally in all four quadrants. 1% voriconazole eye drops were also continued. Cases were examined daily for 1 week and then every week for 4 weeks.

**Results:** Out of 30 patients, 24 patients (80%) showed significant improvement after 4 week, 3 patients (10%) did not show any improvement and 3 patients (10%) got worsened and ultimately managed with therapeutic keratoplasty.

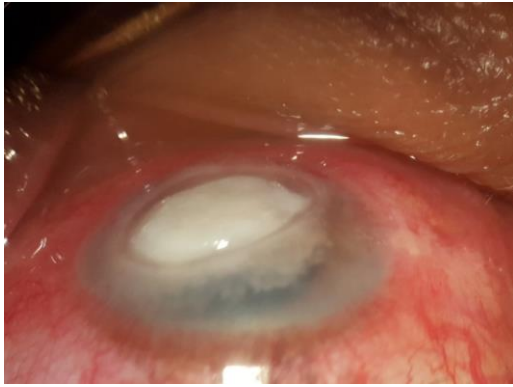**Conclusion:** Intrastromal voriconazole is highly efficacious in recalcitrant fungal keratitis. It is just an OPD procedure. It may not only save the eye but less number of patients will require therapeutic keratoplasty.

**Keywords:** Fungal keratitis, mycotic keratitis, voriconazole

### Introduction

Mycotic keratitis, commonly known as fungal keratitis, accounts for approximately 1-44% of all cases of microbial keratitis, depending upon the geographic location [1, 2]. Overall, it is more common in tropical and subtropical areas. The genera that commonly cause infection of the cornea include *Fusarium*, *Aspergillus*, *Curvularia*, *Bipolaris*, and *Candida* [3]. Most of the currently available antifungal medications have poor bioavailability and limited ocular penetration, especially in cases with deep-seated lesions [4-6]. These factors, especially in cases of severe fungal keratitis and deep stromal infiltration, account for the slow resolution of fungal infections, with most cases finally requiring a therapeutic penetrating keratoplasty [6]. In developing countries most common risk factor for fungal keratitis is trauma with vegetative matter or objects contaminated with soil [1, 2]. While in developed countries, use of contact lenses (CL) has emerged as an important risk factor for the occurrence of fungal keratitis. In addition to CL wear and ocular trauma, ocular surface disease (OSD) is the third most common risk factor accounting for approximately 29% of cases [6, 7]. Common organisms involved in mycotic keratitis include species of *Aspergillus*, *Fusarium*, *Candida*, *Curvularia* and *Penicillium*. Most of these species are saprobes. The rarely reported fungal pathogens include *Fonsecaea pedrosoi*, *Cylindrocarpon* species, *Scedosporium prolificans* [3]. Patient with mycotic keratitis usually have less symptoms and more signs clinically. Presentation is with gradual onset of pain, grittiness, photophobia, blurred vision and watery or mucopurulent discharge. A fungal corneal ulcer classically presents as a dry, raised lesion with crenate or feathery borders, presence of satellite lesions and a thick convex immobile hypopyon.

Conventional method for diagnosis of mycotic keratitis are staining of corneal scrapings with Gram-stain, 10% potassium hydroxide (KOH) wet mount, lactophenol cotton blue, Giemsa, or calcofluor white [1-3]. Recent advances in diagnosis of fungal keratitis are Polymerase chain reaction, genotyping, confocal microscopy and antifungal susceptibility testing. PCR has emerged as a sensitive and specific test for the diagnosis of fungal keratitis. The advantage of PCR-based tests is that only a small clinical sample is needed for diagnosis and it is rapid. PCR assay takes 4-8 h, whereas positive fungal cultures require on an average of 2-7 days [8-10]. DNA sequence-based methods are used for rapid species identification of an organism. Recent reports suggest that filamentous fungi harbor unique species-specific



**Fig 1:** Recalcitrant fungal keratitis showing dense stromal infiltrate

*In vitro* antifungal agent susceptibility profiles as well as clinical characteristics [11-14]. In vivo confocal microscopy (IVCM) uses a series of pinhole apertures to create optical sections of the cornea. It generates images from the cornea with a resolution of 1  $\mu$ m, which is enough to yield instant imaging of organisms that are larger than a few micrometer such as *Acanthamoeba* cysts and fungal hyphae [15]. The reported sensitivity of IVCM is between 80% and 94%. [16] Unlike bacterial keratitis, susceptibility testing is not that frequently used in fungal keratitis. Although, a number of studies have reported the sensitivity of antifungals but these studies often suffer from the limitation of small sample size and nonuniformity of data reported on MIC or focus on one particular genus or species [17]. Though topical antifungal agents are the first line of treatment in fungal keratitis but many patients do not improve even after intensive instillation of drops. This happens particularly when deeper stroma is involved because of poor bioavailability of drugs and poor penetration. Intrastromal injection will provide higher concentration of drugs in deeper layers and helps in early healing. Voriconazole is a triazole antifungal agent, structurally related to fluconazole but with a fluoropyrimidine group in place of triazole moiety. Similar to other triazole agents, it inhibits the enzyme 14- $\alpha$ -lanosterol demethylase leading to lower levels of ergosterol, which is an essential component of fungal cell wall.

### Material and Methods

30 cases of recalcitrant fungal keratitis were included in our study.

### Indications

1. Not showing good response to topical Natamycin (5%) and Voriconazole (1%) eye drops.
2. More than half of stromal thickness involvement.

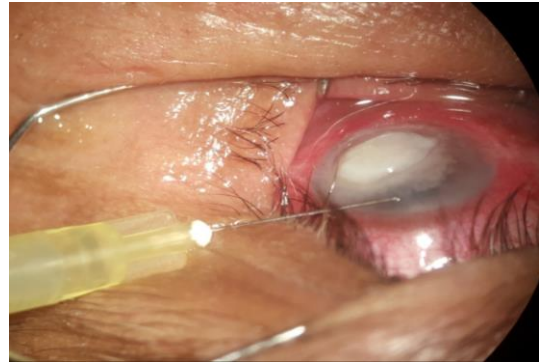
### Contraindications

1. Impending or frank corneal perforation
2. Scleral involvement
3. Endophthalmitis

### Procedure

50 microgram/0.1 ml of voriconazole was constituted. All aseptic precautions were taken. Then 0.1ml injected with a 30G needle in midstroma of junction of clear cornea and stromal infiltrates, divided equally in all four quadrants to form a barrage around ulcer. All patients were given topical and systemic antifungals. 1% voriconazole eye drops were also continued following intrastromal injection. Cases were

examined daily for 1 week and then every week for 4 weeks.



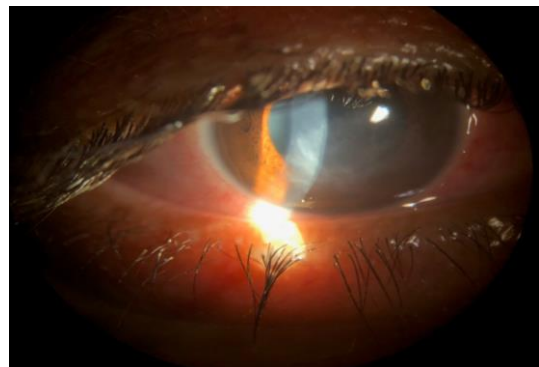
**Fig 2:** Intrastromal voriconazole in recalcitrant fungal keratitis

### Results

Out of 30 patients, 18 patients (60%) showed significant improvement after 1 week, 6 patients (20%) did not show any improvement and 6 patients (20%) got worsened. After 4 weeks, 24 patients (80%) improved significantly, 3 patients (10%) did not improve, 3 patients (10%) got worsened and ultimately underwent therapeutic penetrating keratoplasty.

**Table 1:** Showing response to intrastromal voriconazole

Duration	Improved	Not improved	Worsened	Total
1 week	18(60%)	6(20%)	6(20%)	30
4 week	24(80%)	3(10%)	3(10%)	30



**Fig 3:** Response to intrastromal voriconazole injection after 4 weeks

### Conclusion

Intrastromal voriconazole is highly efficacious in recalcitrant fungal keratitis. It may be given in fungal keratitis cases if topical therapy is not showing desirable response. It is just an OPD procedure and affordable for most patients. It may not only save the eye but less number of patients will require therapeutic keratoplasty.

### References

1. Gower EW, Keay LJ, Oechsler RA, Iovienco A, Alfonso EC, Jones DB *et al.* Trends in fungal keratitis in the United States, 2001 to 2007. *Ophthalmology*. 2010; 117:2263-7.
2. Garg P. Fungal, mycobacterial, and nocardia infections and the eye: An update. *Eye (Lond)*. 2012; 26:245-51.
3. Revankar SG, Sutton DA. Melanized fungi in human disease. *Clin Microbiol Rev*. 2010; 23:884-928.

4. Qiu S, Zhao GQ, Lin J, Wang X, Hu LT, Du ZD *et al.* Natamycin in the treatment of fungal keratitis: A systematic review and Meta-analysis. *Int J Ophthalmol.* 2015; 8:597-602.
5. Ansari Z, Miller D, Galor A. Current thoughts in fungal keratitis: Diagnosis and treatment. *Br J Ophthalmol.* 2013; 7:209-18.
6. Chang HY, Chodosh J. Diagnostic and therapeutic considerations in fungal keratitis. *Int Ophthalmol.* 2011; 51:33-42.
7. Keay LJ, Gower EW, Iovieno A, Oechsler RA, Alfonso EC, Matoba A *et al.* Clinical and microbiological characteristics of fungal keratitis in the United States, 2001-2007: A multicenter study. *Acta Ophthalmol.* 2011; 118:920-6.
8. Thomas PA, Teresa PA, Theodore J, Geraldine P. PCR for the molecular diagnosis of mycotic keratitis. *Expert Rev Mol Diagn.* 2012; 12:703-18.
9. Vengayil S, Panda A, Satpathy G, Nayak N, Ghose S, Patanaik D *et al.* Polymerase chain reaction-guided diagnosis of mycotic keratitis: A prospective evaluation of its efficacy and limitations. *Invest Ophthalmol Vis Sci.* 2009; 50:152-6.
10. Tananuvat N, Salakthuantee K, Vanittanakom N, Pongpom M, Ausayakhun S. Prospective comparison between conventional microbial work-up vs PCR in the diagnosis of fungal keratitis. *Eye (Lond).* 2012; 26:1337-43.
11. Homa M, Shobana CS, Singh YR, Manikandan P, Selvam KP, Kredics L *et al.* *Fusarium* keratitis in South India: Causative agents, their antifungal susceptibilities and a rapid identification method for the *Fusarium solani* species complex. *Med. Mycol.* 2013; 56:501-11.
12. Azor M, Gené J, Cano J, Manikandan P, Venkatapathy N, Guarro J. Less-frequent *Fusarium* species of clinical interest: Correlation between morphological and molecular identification and antifungal susceptibility. *J Clin Microbiol.* 2009; 47:1463-8.
13. Wang H, Xiao M, Kong F, Chen S, Dou HT, Sorrell T, *et al.* Accurate and practical identification of 20 *Fusarium* species by seven-locus sequence analysis and reverse line blot hybridization, and an in vitro antifungal susceptibility study. *J Clin Microbiol.* 2011; 49:1890-8.
14. Alastruey-Izquierdo A, Cuenca-Estrella M, Monzón A, Mellado E, Rodríguez-Tudela JL. Antifungal susceptibility profile of clinical *Fusarium* spp. isolates identified by molecular methods. *J Antimicrob Chemother.* 2008; 61:805-9.
15. Homa M, Shobana CS, Singh YR, Manikandan P, Selvam KP, Kredics L *et al.* *Fusarium* keratitis in South India: Causative agents, their antifungal susceptibilities and a rapid identification method for the *Fusarium solani* species complex. *Med. Mycol.* 2013; 56:501-11.
16. Azor M, Gené J, Cano J, Manikandan P, Venkatapathy N, Guarro J. Less-frequent *Fusarium* species of clinical interest: Correlation between morphological and molecular identification and antifungal susceptibility. *J Clin Microbiol.* 2009; 47:1463-8.
17. Kumar RL, Cruzat A, Hamrah P. Current state of in vivo confocal microscopy in management of microbial keratitis. *Semin Ophthalmol.* 2010; 25:166-70.