



E-ISSN: 2663-8274
P-ISSN: 2663-8266
www.ophthalmoljournal.com
IJMO 2023; 5(1): 20-24
Received: 18-11-2022
Accepted: 25-12-2022

Dr. Veeresh Korwar
M.R Medical College,
Kalaburagi, Karnataka, India

Dr. Renuka Kanthi
M.R Medical College,
Kalaburagi, Karnataka, India

Dr. Anup
M.R Medical College,
Kalaburagi, Karnataka, India

Corresponding Author:
Dr. Veeresh Korwar
M.R Medical College,
Kalaburagi, Karnataka, India

Clinical outcome of Tenon's patch graft and bandage contact lens in cases of corneal perforation

Dr. Veeresh Korwar, Dr. Renuka Kanthi and Dr. Anup

DOI: <https://doi.org/10.33545/26638266.2023.v5.i1a.135>

Abstract

Background: Corneal perforation is a leading cause of ocular morbidity around the world. It may occur due to trauma to the eye, keratitis, and many other conditions. Any corneal perforation should be treated immediately and promptly to avoid complications and subsequently corneal blindness.

Objective: To describe effectiveness of using autologous Tenon's tissue along with bandage contact lens to manage corneal perforations less than 3 mm in size.

Methods: Tenon's patch graft was done in five cases of corneal perforation. Informed consent was obtained from the subjects after explanation of the nature and possible consequences of the study and this study was approved by ethical committee.

Results: Of the five patients the first patient she showed good integration of the Tenon's Patch Graft (TPG). She had a vision of Perception of Light+ and accurate projection of rays after a period of 5 months post procedure. The wound healed with a glaucomatous scar. Case two had a vision of counting fingers close to face after five months. Case three showed good integration of the TPG. He had a vision of 6/60 accurate after a period of three months post procedure. In case four anterior chamber was shallow, post patch integrity was not maintained. Patient was later considered for penetrating keratoplasty. Case five showed integration of TPG after one week postop with vision counting fingers at 6 meters.

Conclusion: We conclude that Tenon's Patch Graft with bandage contact lens is an effective technique in the treatment of corneal perforations. Using this, the integrity of the eyeball can be maintained without any danger of graft rejection since the tissue is autologous. This technique can be used effectively in places where resources are scant.

Keywords: Ocular morbidity, Tenon's patch graft (TPG), eye, keratitis, blindness

Introduction

Corneal blindness is the second most common cause of preventable blindness in developing countries like India [1, 2]. Globally, the commonest causes for corneal blindness in adults include corneal ulcerations and corneal trauma [2].

Corneal perforations may occur because of trauma, supportive corneal ulcers, or secondary to immunological disorders and dry eyes. A corneal perforation is an ocular emergency requiring prompt closure of the corneal defect. If the perforation is large, or not satisfactorily managed, extrusion of the intraocular contents through the perforation may occur. This can lead to loss of integrity of the eyeball, resulting in permanent blindness.

Prompt closure of the corneal defect with adequate treatment of the underlying pathology will result in healing. The goal of treatment of corneal perforations is to restore eyeball integrity and enable appropriate healing to occur.

Materials and Methods

The present study was carried for a period of 19 months from 1st march 2021 to 1st November 2022 on patients attending the ophthalmology out-patient department at Basaweshwar Teaching and General Hospital, Gulbarga with corneal perforation. Perforation of mean size 2.00 ± 0.9 mm were selected.

Before operating, the patients were explained in detail regarding the procedure, and then an informed and written consent was taken. The surgery was performed under per bulbar block. The eye was scrubbed and draped. The wound edges were freshened and stromal pocket created around the wound margin. Then, conjunctively preatomic was done and exposed in the upper part of the eye. Thereafter, the conjunctiva was separated from the Tenon's tissue by blunt dissection using conjunctively scissors.

The Tenon’s tissue, of applicable size, was attained by blunt dissection of underlying Episcleral tissue. The gathered Tenon’s tissue was placed over the wound and gently tucked into the stromal pocket of cornea. It was then sutured using 10-0 Ethicon monofilament using overlay sutures. Anterior chamber was well formed with air and a bandage contact lens was placed over cornea.

Postoperative follow-up was performed at Day 1, Day 7, Day 15, Day 30, and 5 months by slit lamp examination. Anterior chamber formation, post-patch integration, inflammation and corneal stromal thickness stability were

the main assessment factors.

Results

The baseline characteristics of patients are represented in [Table 1].

Of the five patients, one of them had to undergo penetrating keratoplasty because of poor patch integrity. In rest of the four cases, intraoperative anterior chamber was formed which was maintained throughout the follow-up period. The graft was accepted well.

Table 1: Baseline characteristics of the patients

VARIABLES	CASE 1	CASE 2	CASE 3	CASE 4	CASE 5
AGE (YEARS)	50	70	60	51	55
GENDER	Female	Male	Male	Male	Male
ETIOLOGY	Fungal Corneal Ulcer	Fungal Corneal Ulcer	Microbial Keratitis	Trauma by Stone	Fungal Corneal Ulcer
SITE OF PERFORATION	Central	Paracentral	Below Pupillary margin	Central	Below Pupillary margin
SIZE OF PERFORATION	2-3mm	2mm	2mm	3mm	2-3mm
COMORBIDITIES	Nil	Hypertensive	Nil	Diabetic	Nil
VISUAL ACUITY AT LAST VISIT	Perception of light+ Accurate projection	Counting fingers close to face	6/60	Perception of light+ Accurate projection	Counting Fingers at 6 meters.

Case 1 was a patient with left eye central corneal perforation due to fungal corneal ulcer measuring 2-3mm with iris prolapse [Figure 1a]. She showed good integration of the

TPG. She had a vision of Perception of light+ and accurate projection of rays after a period of 5 months post procedure. The wound healed with a glaucomatous scar [Figure 1b].

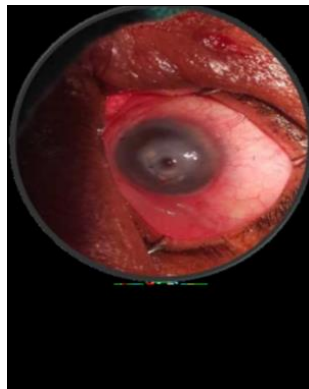


Fig 1(a): Preoperative image showing Central corneal perforation.

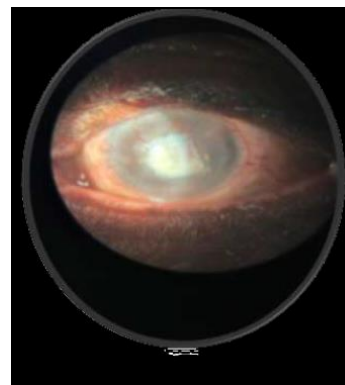


Fig 1(b): Glaucomatous scar after 5 months post operation.

Case 2 was a patient with left eye necrotizing stromal keratitis with par central corneal perforation [Figure 2a]. He

showed good integration of the TPG [Figure 2b]. He had a vision of counting fingers close to face after 5 months.

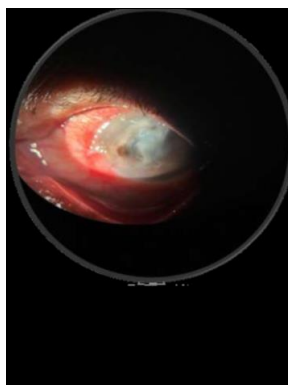

Fig 2(a): Preoperative image showing Left eye necrotizing stromal keratitis With par central corneal perforation.

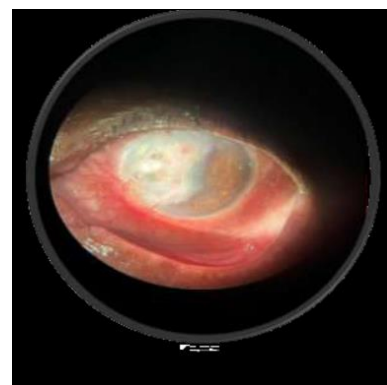


Fig 2(b): Post-operative image after 5 months showing good Integration of TPG.

Case 3 was a patient with right eye perforated microbial keratitis below pupillary area measuring around 3mm [Figure 3a]. He showed good integration of the TPG [Figure

3b]. He had a vision of 6/60 after period of 3 months post procedure.

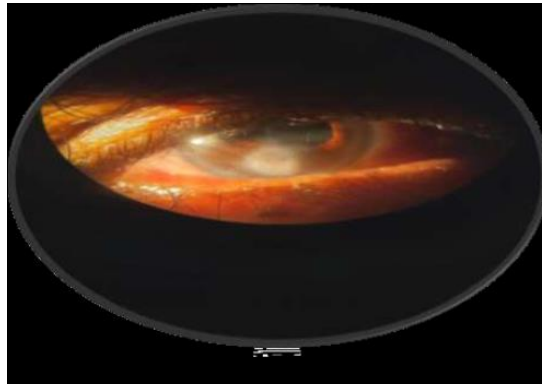
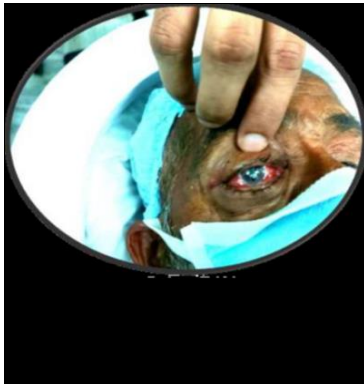


Fig 3(a): Preoperative image showing Perforated microbial keratitis. **Fig 3(b):** Post-operative image after 5 months.

Case 4 was a patient with right eye central corneal perforation due to trauma by stone particle [Figure 4a]. Went to traditional healer and later patient presented with corneal perforation. Tenon's patch graft was done.

However, on post-operative day-5 anterior chamber was shallow, post patch integrity was not maintained [Figure 4b]. Patient was later considered for penetrating keratoplasty.

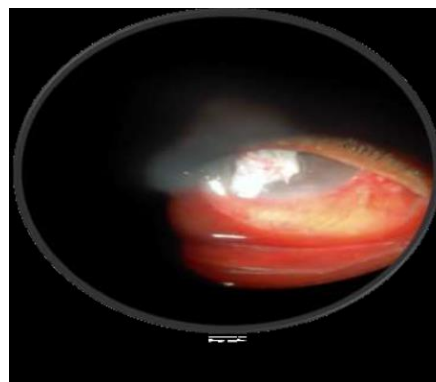
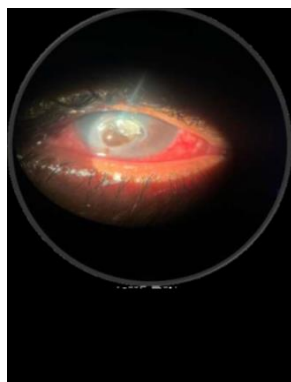


Fig 4(a): central corneal perforation.

Fig 4(b): Post-op day 5 image showing poor Post patch integrity.

Case 5 was a patient with left eye perforated fungal corneal ulcer [Figure 5a], with vision-counting fingers at ½ m, with endothelial plaque protruding out of perforated site. He showed integration of TPG after 1 week post-op [Figure 5b]

with vision of counting fingers at 6meters. None of the patients were lost to follow-up and showed no signs of wound leak at the end of POD 30.

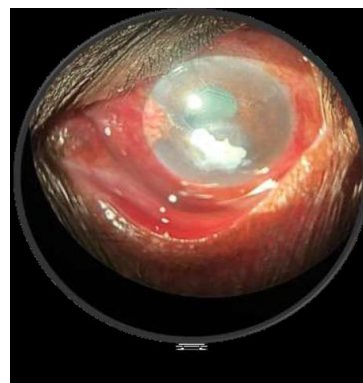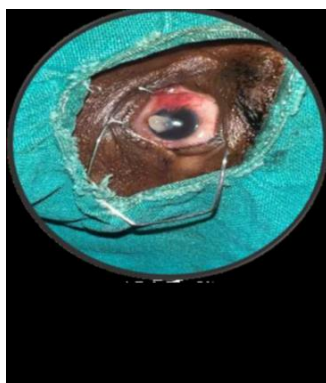


Fig 5(a): perforated fungal corneal ulcer.

Fig 5(b): 1 week post-op image showing Good integrity of TPG.

None of the patients were lost to follow-up and showed no signs of wound leak at the end of POD 30.

Discussion

Tenon's Patch Graft is a very simple and a very feasible option in management of small to moderate corneal

perforations. Hence a proper understanding of the anatomy, advantages and disadvantages of Tenon's patch grafting is of utmost importance.

Anatomy

- Located between conjunctively stromal & episclera.
- Posteriorly, merges with dual sheath of optic nerve.
- Separates orbital fat from contact with the sclera.
- The Tenon's capsule begins about 2 mm posterior to

the limbs and is composed of two parts.

- The anterior part is a thick fibrous tissue with smooth muscle fibres and fibroblasts,
- The posterior part is thin fibrous capsule of the orbital fat. (Figure 6)
- The Tenon's tissue is postulated to produce autologous fibroblasts and connective tissue, which allows it to be incorporated in the healed corneal tissue.

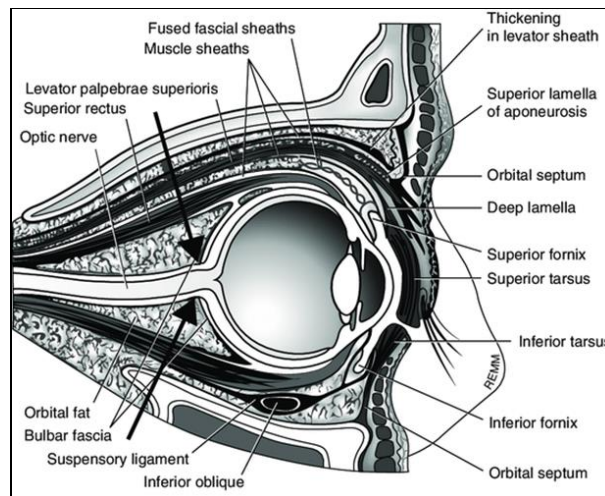


Fig 6: Anatomy of the Tenon's Capsule

Indications of TPG: Peripheral Ulcerative Keratitis [3], Traumatic corneal perforations [3], neurotropic keratitis [3], Leaking trabeculectomy blebs [4], Scleromalacia after pterygium excision [5], Traumatic scleral perforation [6], corneal fistulas [7].

Advantages of TPG are that it is available easily and in abundance, and there is No need of donor cornea hence eliminates risk of disease transmission as it is autologous.

There are multiple techniques of TPG

1. Tenon's patch graft alone –sutured or tucked –in
2. Tenon's patch graft sutured with AMG overlay
3. Tenon's patch graft with AMG overlay sutured
4. Tenon's patch graft with fibrin glue

There have been various materials, allogeneic, and autologous, which are being used to aid and provide tectonic support in corneal fistulas, sclera-corneal wounds, and pterygium surgeries [8-10].

The alternatives to TPG include tissue adhesives like cyanoacrylate glue, AMG, penetrating keratoplasty, lamellar grafts, temporalis fascia late, and periosteal, each one having their own set of advantages and disadvantages [11]. While some of these alternatives need a second surgery to harvest the tissue, the others need donor tissue. The main issue with using an allogeneic material is that they carry an increased risk of tissue rejection and infection. The goal of treatment of corneal perforations is to restore globe integrity, and allow healing of the defect. Although the use of autologous and lab-cultured Tenon's tissue for case of post trabeculectomy bleb site leak and pterygium surgeries has been reported before, the mention of the use of TPG to treat corneal perforations is very rare [12-14].

The drawbacks of the technique are that the TPG can be used for sterile corneal perforations of size 3-5mm only.

Perforations of size larger than 5 mm need a patch graft as the support provided by TPG is inadequate.

In our technique, we harvested Tenon's tissue from the superior quadrant, as the tissue from the inferior quadrant carries a risk of getting infected due to inadequate closure by the lids. Harvesting the tissue from the medial or lateral side is avoided as it can cause mild restriction of extra ocular movement, due to the tug on medial and lateral ligaments respectively.

Conclusion

We conclude that Tenon's Patch Graft with bandage contact lens is an effective technique in the treatment of corneal perforations. Using this, the integrity of the eyeball can be maintained without any danger of graft rejection since the tissue is autologous. This technique can be used effectively in places where resources are scant.

References

1. Oliva MS, Schottman T, Gulati M. Turning the tide of corneal blindness. *Indian J Ophthalmology*. 2012;60(5):423-7. DOI: 10.4103/0301-4738.100540. PMID: 22944753; PMCID: PMC3491269.
2. Whitcher JP, Srinivasan M, Upadhyay MP. Corneal blindness: a global perspective. *Bull World Health Organ*. 2001;79(3):214-21. Pub 2003 Jul 7. PMID: 11285665; PMCID: PMC2566379.
3. Korah S, Selvin SS, Pradhan ZS, Jacob P, Kuriakose T. Tenon's Patch Graft in the Management of Large Corneal Perforations. *Cornea*. 2016;35(5):696-9. DOI: 10.1097/ICO.0000000000000808. PMID: 26989954.
4. Morris DA, Ramocki JM, Shin DH, Glover BK, Kim YY. Use of autologous Tenon's capsule and scleral patch grafts for repair of excessively draining fistulas with leaking filtering blebs. *J Glaucoma*. 1998;7(6):417-9. PMID: 9871865
5. Jong Soo Lee, Min Kyu Shin, Jong Ho Park, Young

- Min Park, Margaret Song. Autologous Advanced Tenon Grafting Combined with Conjunctiva Flap in Scleromalacia after Pterygium Excision, *Journal of Ophthalmology*, vol. 2015, Article ID 547276; c2015, 6. <https://doi.org/10.1155/2015/547276>
6. JiHyun Bae, Hyun Kyoung Seong, Ha Kyoung Kim, Woo Ho Nam. Use of Autologous Tenon's Capsule Graft for Repair of Traumatic Scleral Perforation. *Journal of the Korean Ophthalmological Society*. 2008;49(10):1706-1710.
 7. Singhal D, Sahay P, Maharana PK, Amar SP, Titiyal JS, Sharma N. Clinical presentation and management of corneal fistula. *Br J Ophthalmology*. 2019;103(4):530-533. DOI: 10.1136/bjophthalmol-2018-312375. Pub 2018 May 29. PMID: 29844083.
 8. Maharana PK, Singhal D, Sahay P, Titiyal JS. Tenon patch graft for corneal fistula: a rare entity treated by a simple technique. *BMJ Case Rep*. 2017 Nov 23; 2017:bcr2017222790. DOI: 10.1136/bcr-2017-222790. PMID: 29170188; PMCID: PMC5720249./.
 9. Bae JH, Seong HK, Kim HK, Nam WH. Use of Autologous Tenon's Capsule Graft for Repair of Traumatic Scleral Perforation. *J Korean Ophthalmology Soc*. 2008;49(10):1706-1710.
 10. Agarwal T, Gupta S, Sharma N. *Textbook of Pterygium Management*, Jaypee Brothers Medical Publications; c2017. p. 137-9.
 11. Deshmukh R, Stevenson LJ, Vajpayee R. Management of corneal perforations: An update. *Indian J Ophthalmology*. 2020;68(1):7-14. DOI:10.4103/ijo.IJO_1151_19. PMID: 31856457; PMCID: PMC6951192.
 12. Kawai M, Nakabayashi S, Shimizu K, Hanada K, Yoshida A. Autologous Transplantation of a Free Tenon's Graft for Repairing Excessive Bleb Leakage after Trabeculectomy: A Case Report. *Case Rep Ophthalmology*. 2014;5(3):297-301. DOI: 10.1159/000368159. PMID: 25408669; PMCID: PMC4224260.
 13. Hong S, Yun JH, Kim ES, Kim JS, Tchah H, Hwang C. Human Conjunctiva Epithelial Sheets Grown on Poly(Lactic-Co-Glycolic) Acid Membranes and Cultured With Human Tenon's Fibroblasts for Corneal Repair. *Invest Ophthalmology Vis Sci*. 2018;59(3):1475-1485. DOI: 10.1167/iovs.17-22719. PMID: 29625470.
 14. De Falco E, Scafetta G, Napoletano C, Puca R, Vingolo EM, Ragona G, *et al*. A standardized laboratory and surgical method for *in vitro* culture isolation and expansion of primary human Tenon's fibroblasts. *Cell Tissue Bank*. 2013;14(2):277-87. DOI: 10.1007/s10561-012-9325-1. Epub 2012 Jul 21. PMID: 22820760.

How to Cite This Article

Korwar V, Anup. Clinical outcome of Tenon's patch graft and bandage contact lens in cases of corneal perforation. *International Journal of Medical Ophthalmology*. 2023;5(1):20-24.

Creative Commons (CC) License

This is an open access journal, and articles are distributed under the terms of the Creative Commons Attribution-Non Commercial-Share Alike 4.0 International (CC BY-NC-SA 4.0) License, which allows others to remix, tweak, and build upon the work non-commercially, as long as appropriate credit is given and the new creations are licensed under the identical terms.